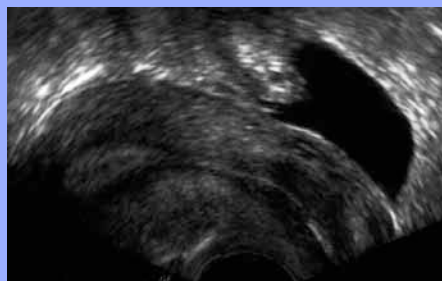


Radiologdagar Örebro 21.9.2010

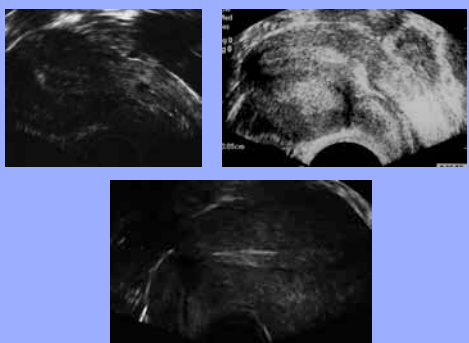


Berit Gull  
Överläkare  
Kvinnokliniken SU/Sahlgrenska

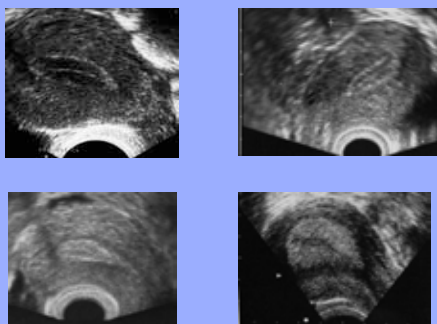
Uterus sagittalt



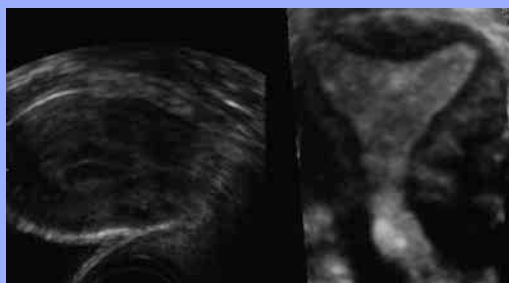
Uterus efter sectio



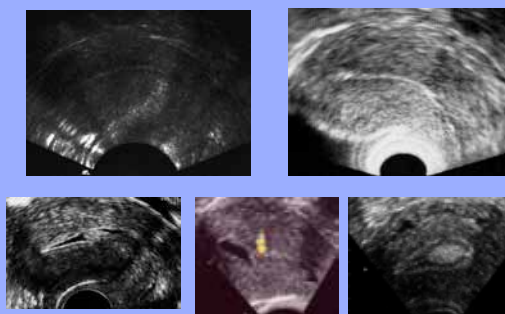
Endometrium : cykelförändring

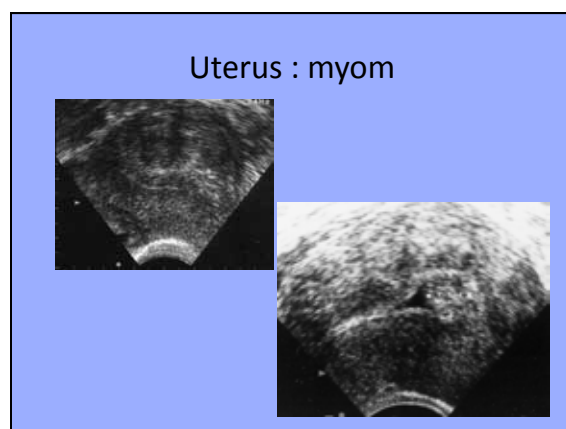
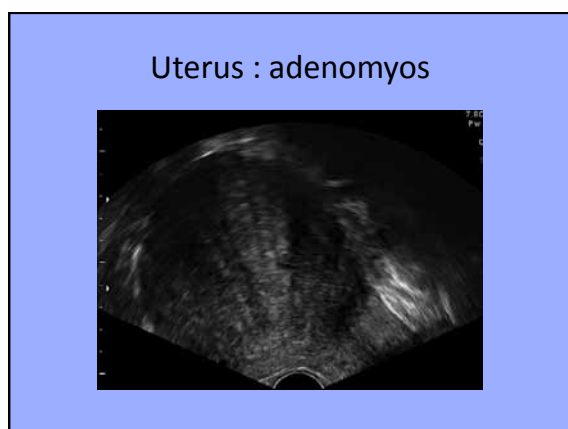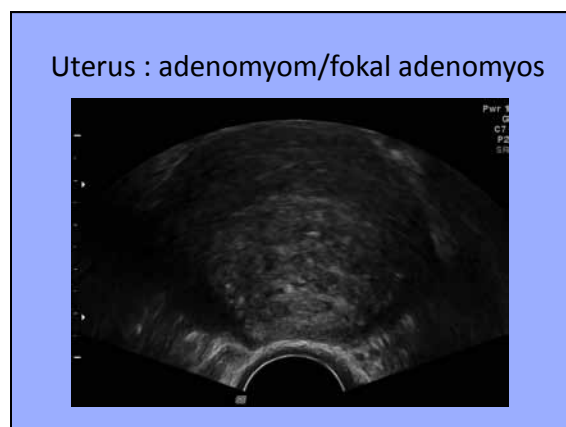
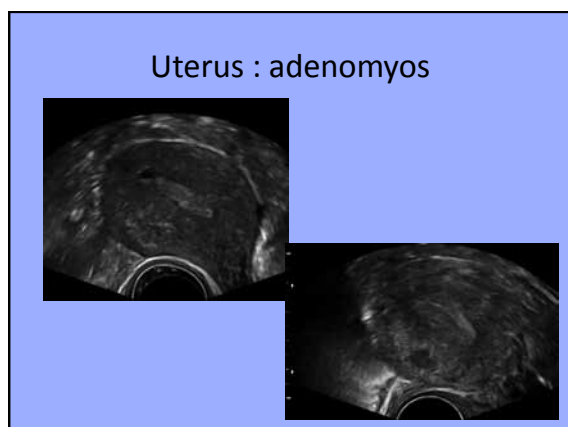
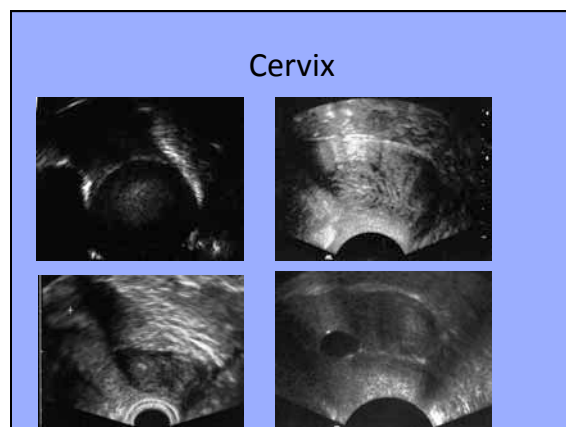
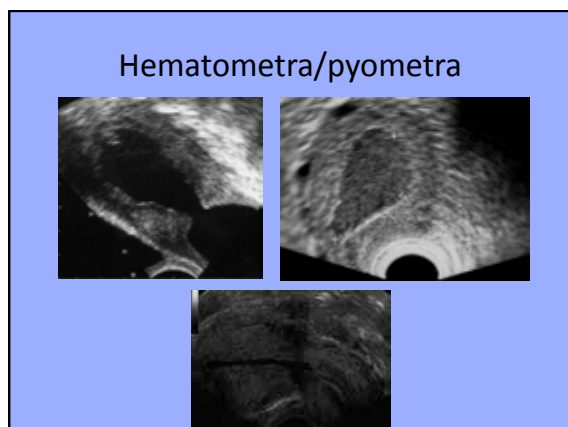


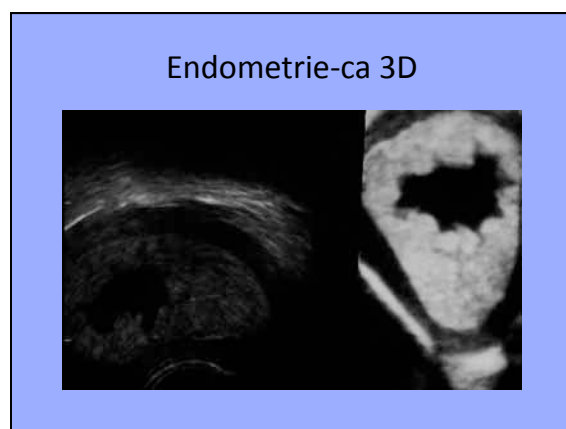
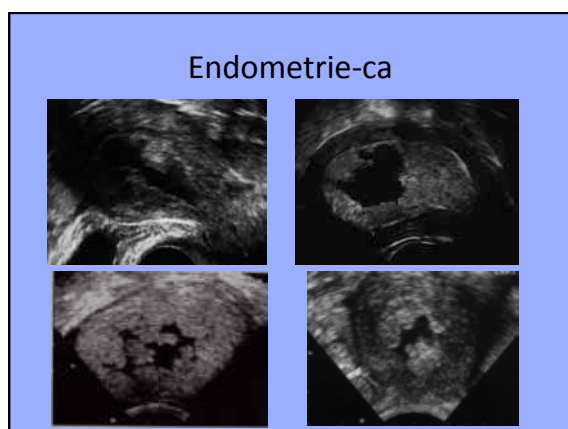
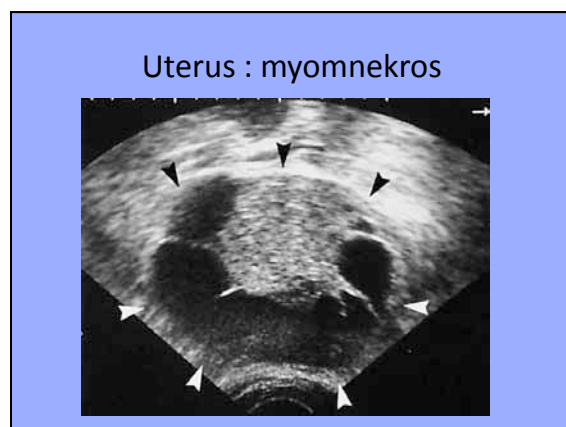
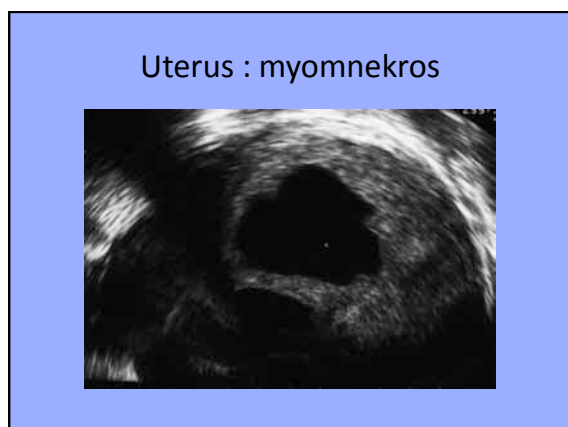
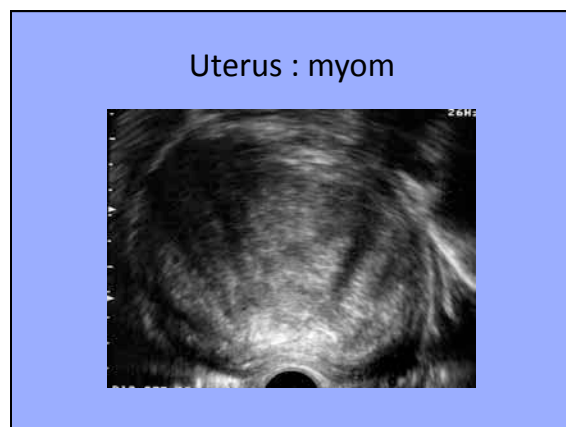
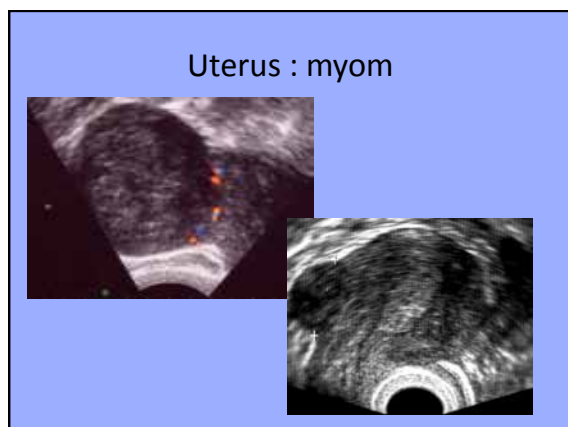
Endometrium/Uterus 3D



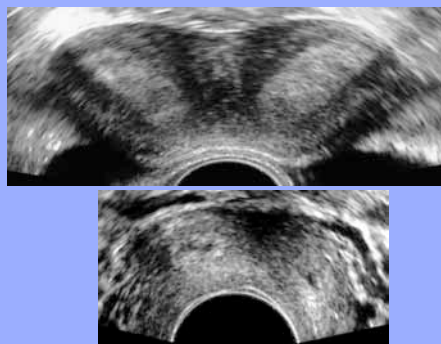
Endometrium : atrofi/polyp



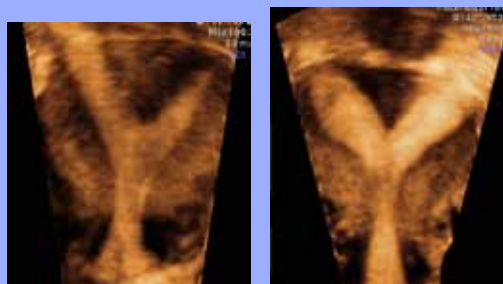




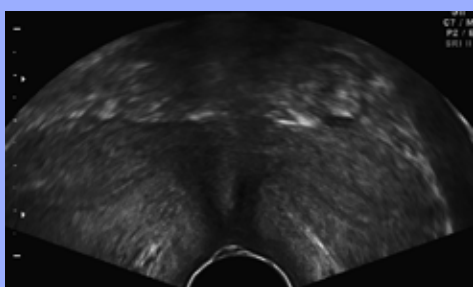
Uterusvarianter



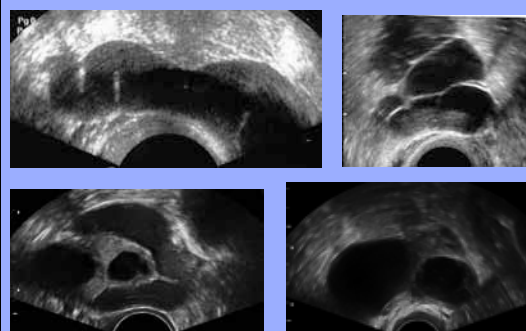
Bicorn uterus 3D



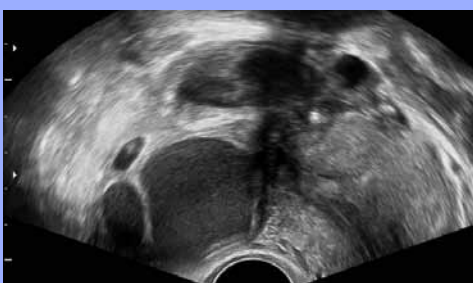
Uterus duplex



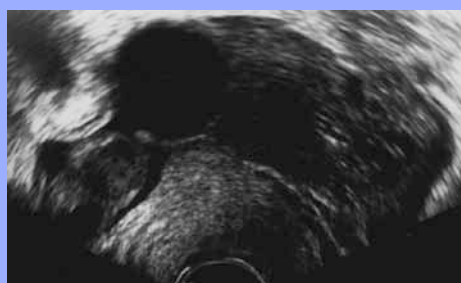Tubor

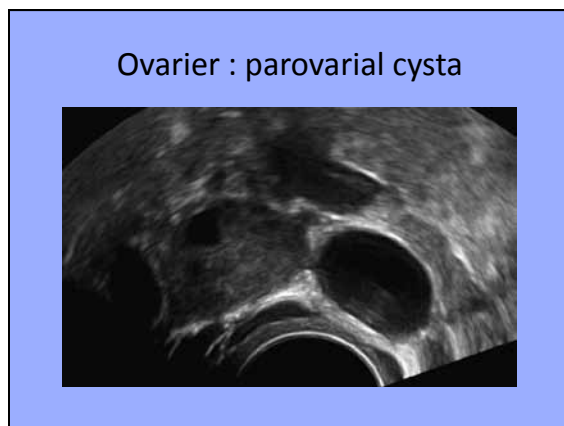
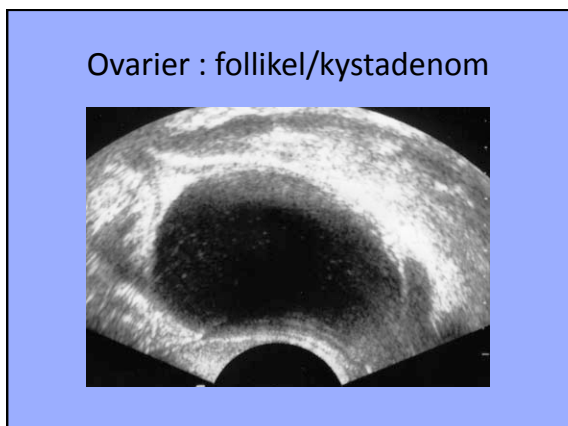
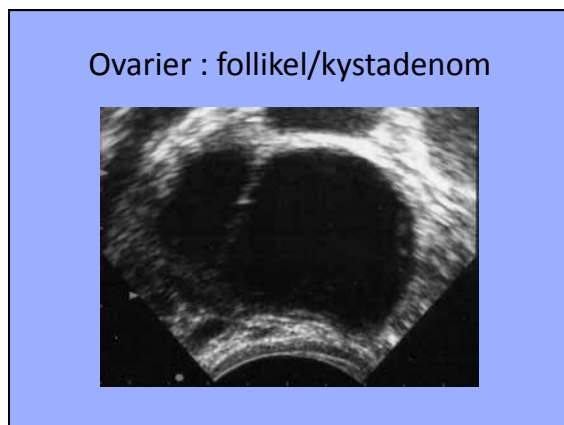
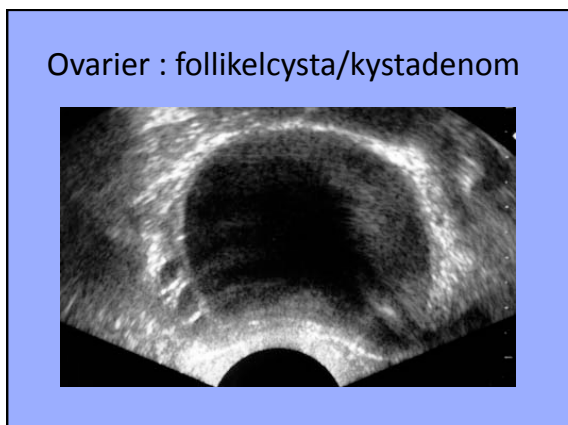
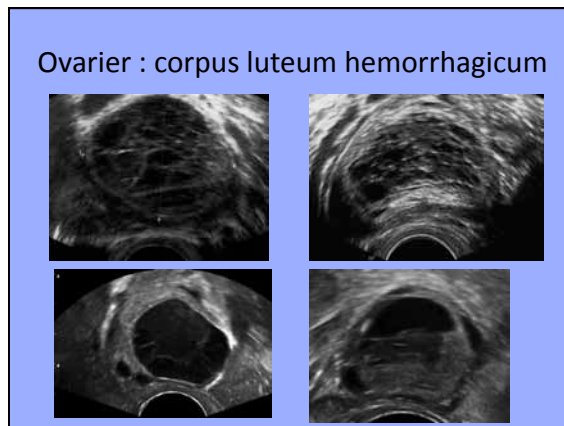
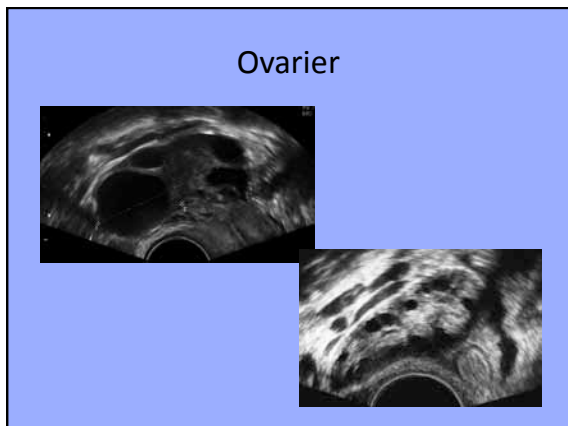


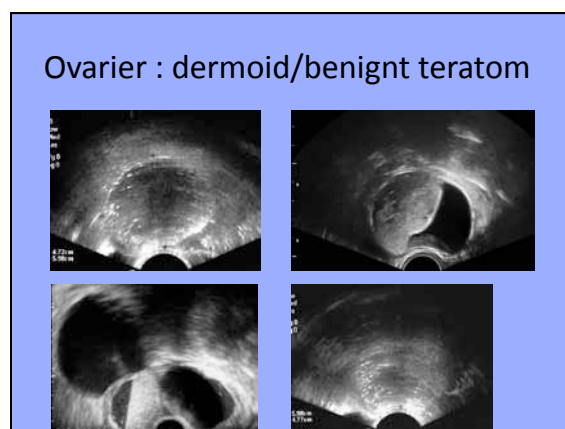
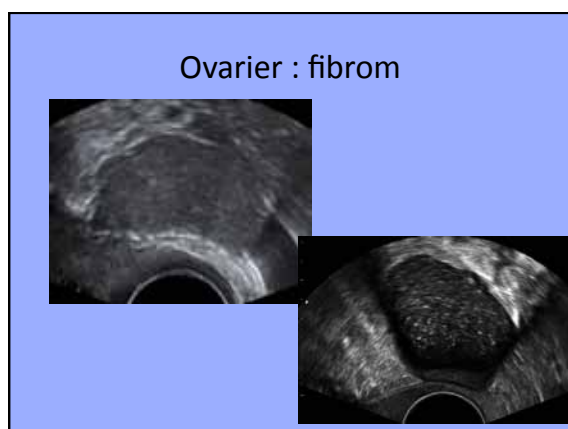
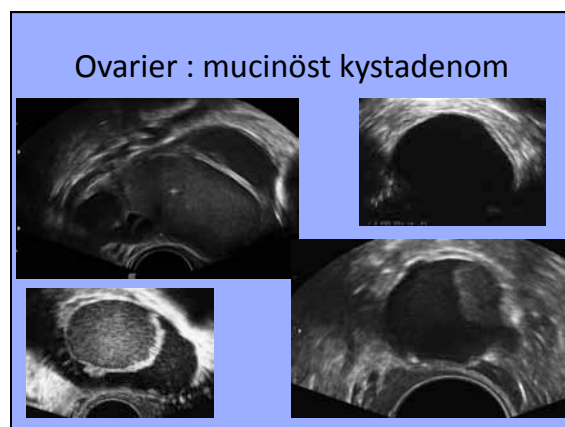
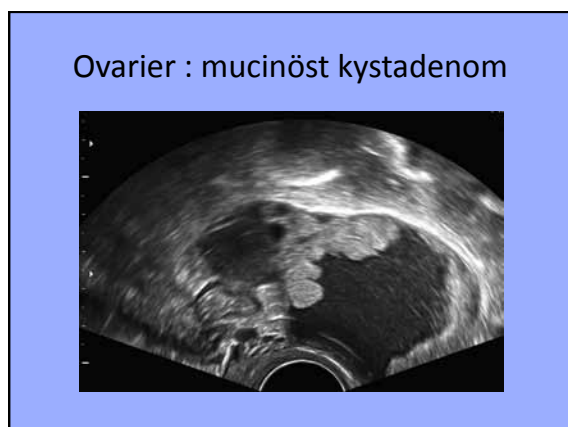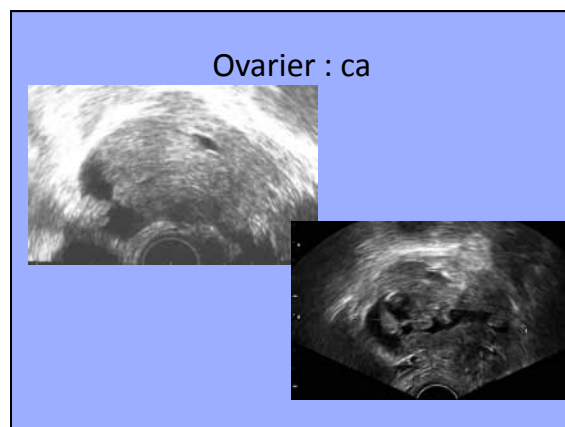
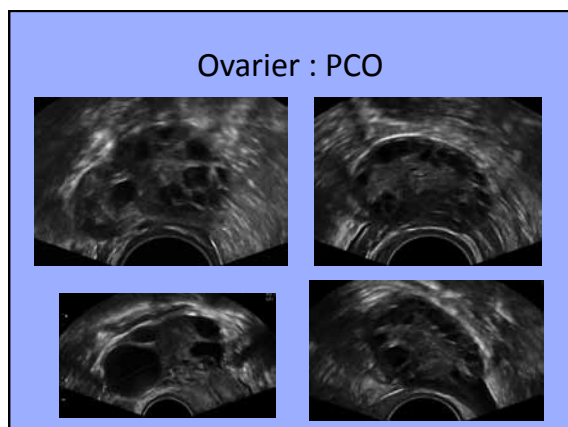
Tubo-ovarial-abscess

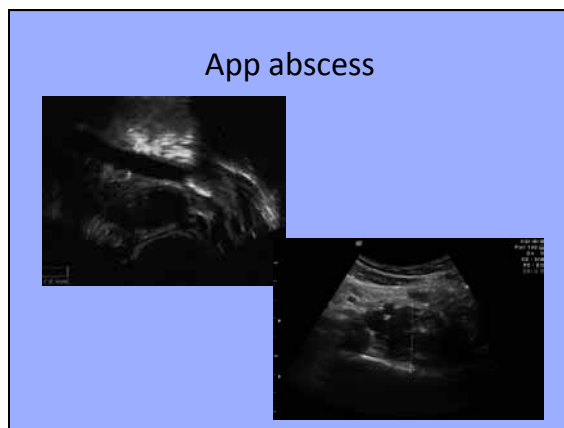
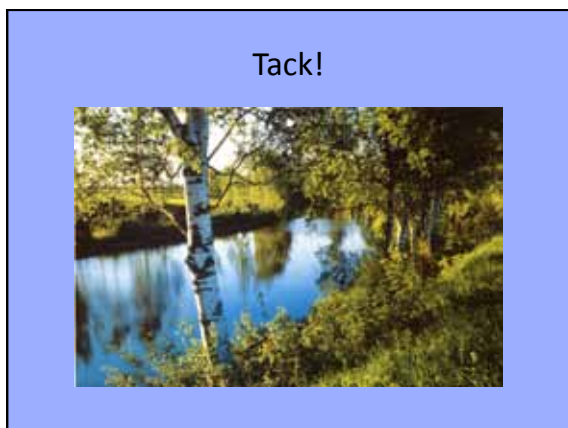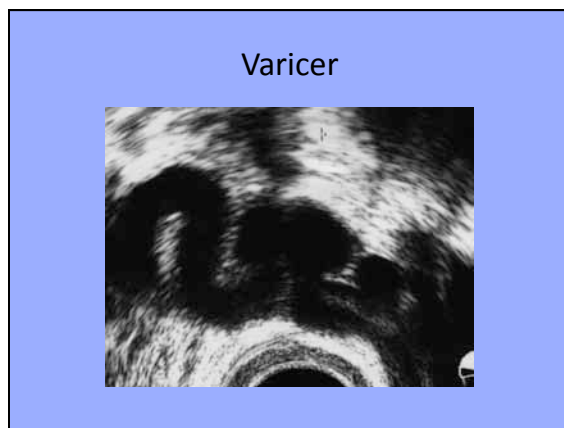
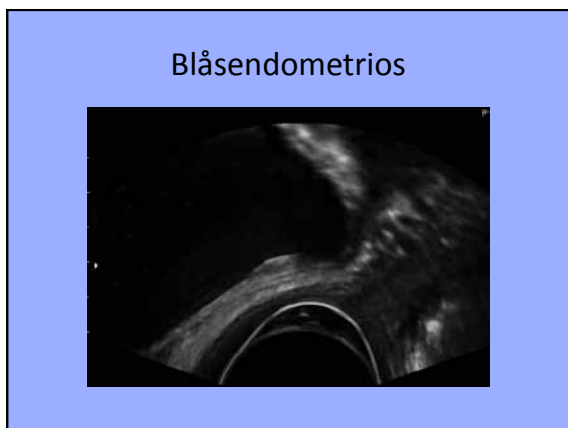
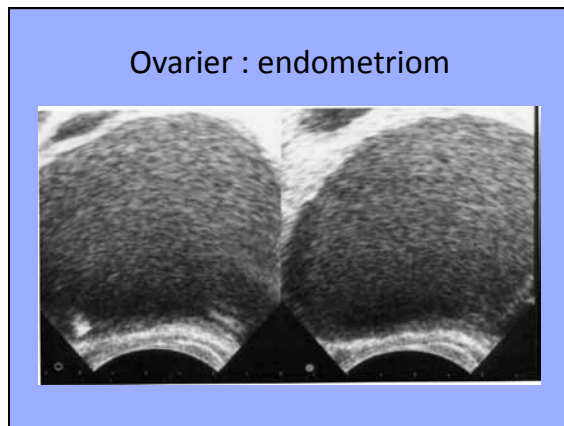
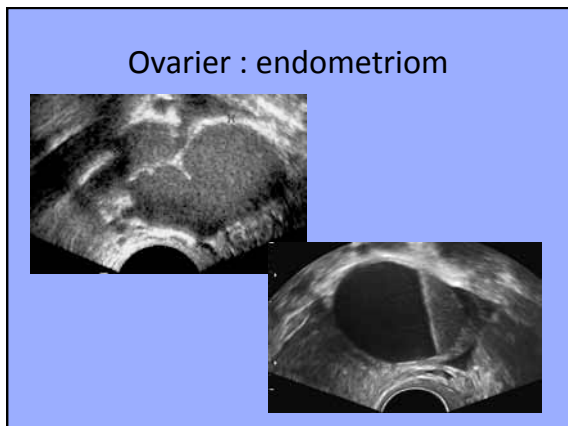


Ovarier : torsion

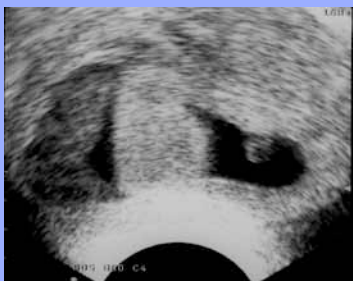



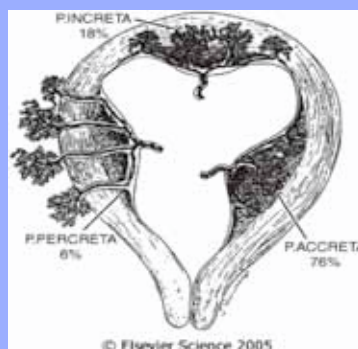




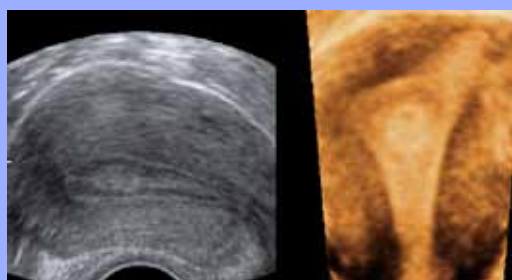
Placenta-avlossning



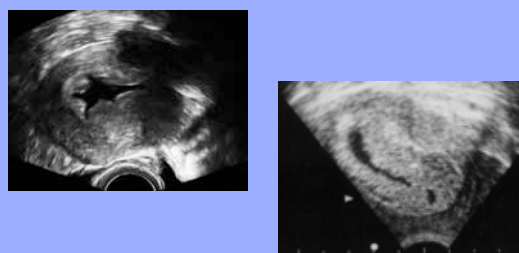Placenta



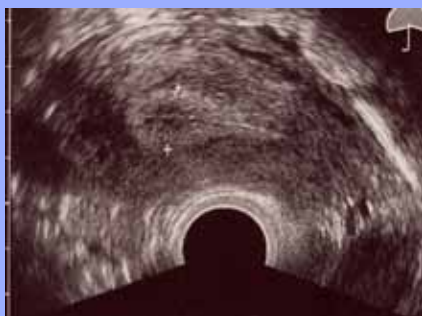Endometrium 3D : polyp



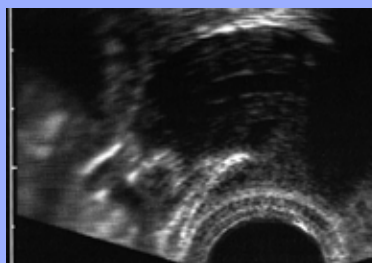
Endometriumhyperproliferation/  
hyperplasi



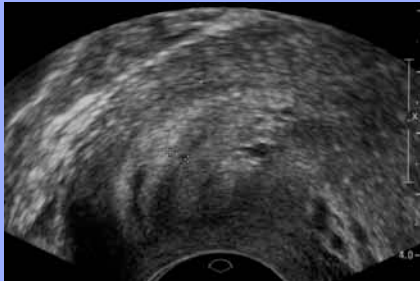
Uterus sagittalt



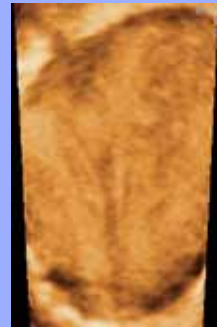Vätska i kaviteten



Uterus duplex



Uterus duplex 3D



Ovarier : corp lut hem

