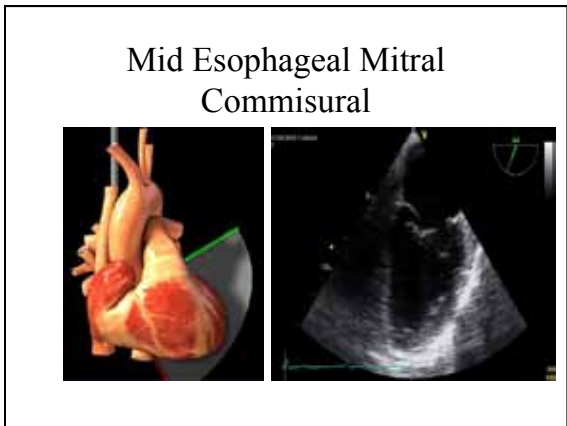
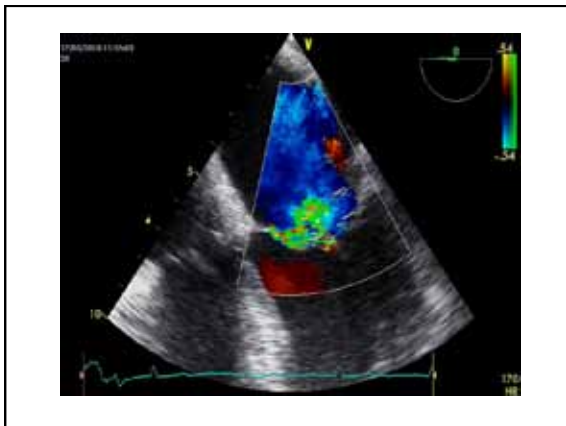
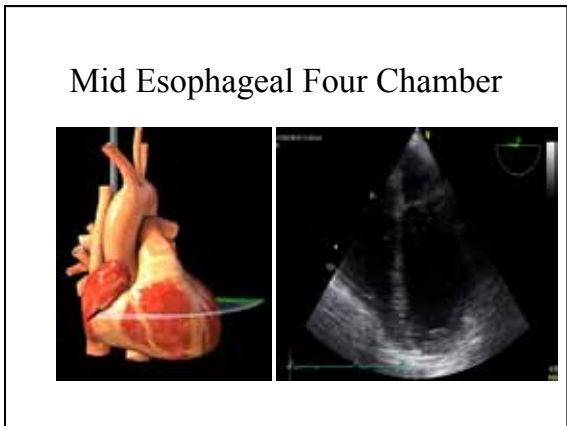
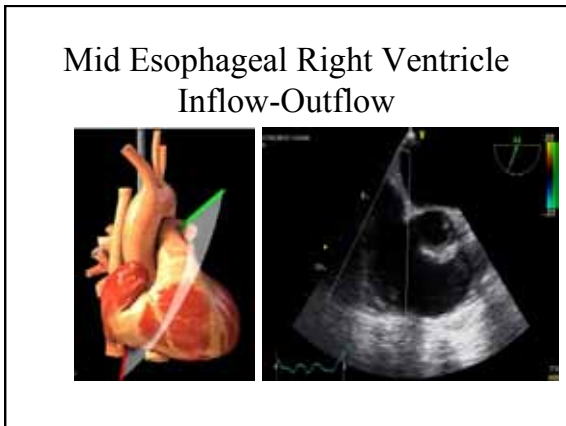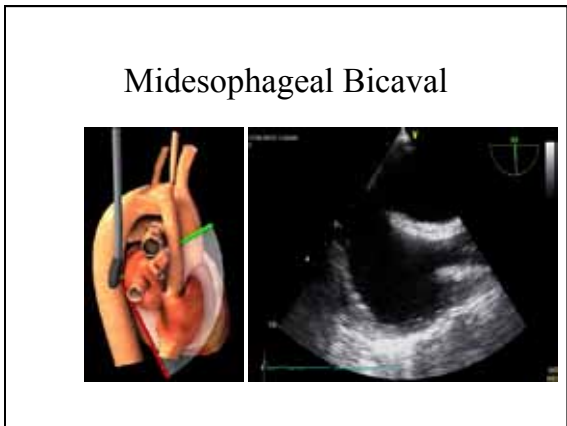
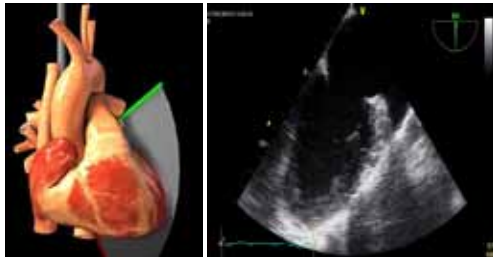


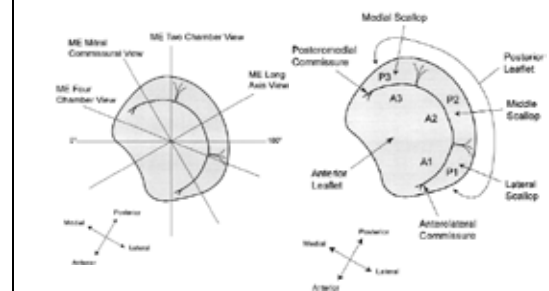
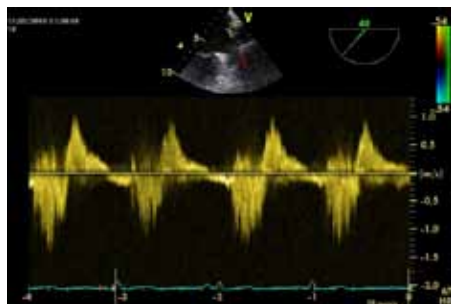
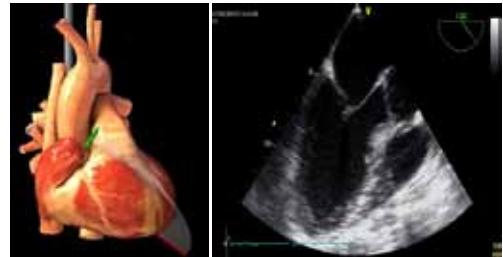**PEROPERATIV  
TRANSESOFAGEAL  
EKOKARDIOGRAFI**  
Tor Damén  
Thoraxkliniken, USÖ



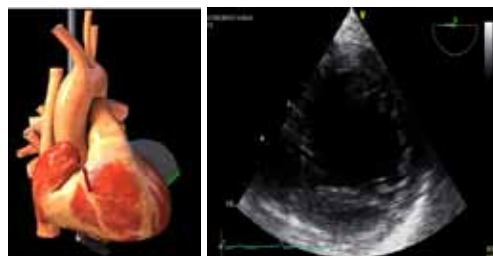### Mid Esophageal Two Chamber



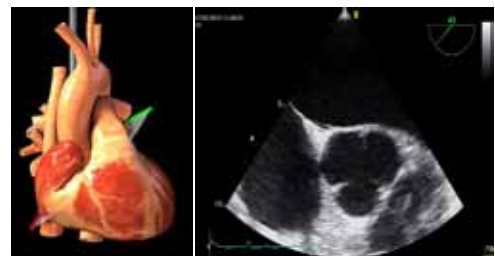
### Mid Esophageal LAX



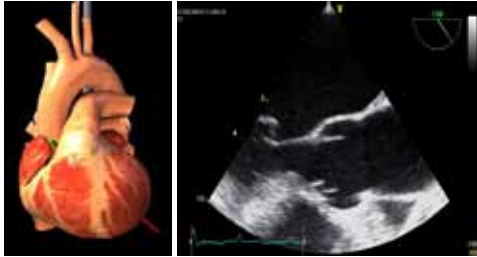
### Transgastric Mid SAX



### Mid Esophageal Aortic Valve SAX



### Mid Esophageal Aortic Valve LAX



- Morfologi
- Dimensioner (preload)
- VK och HK funktion
- Klaffpatologi

