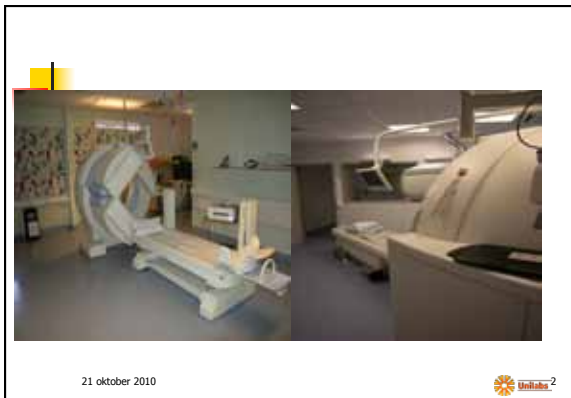
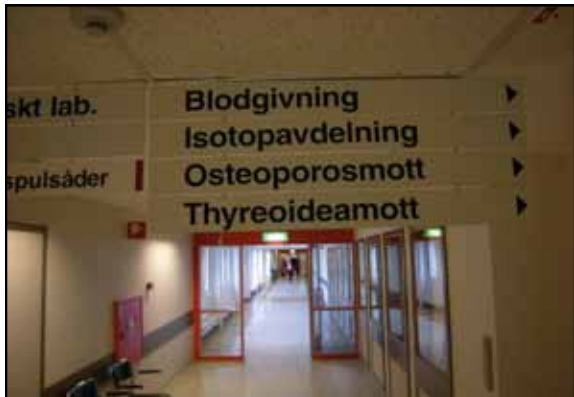




### PERSONAL

- 6 sjuksköterskor/BMA
- 1/2 RAD/NUK (radiolog/nukleärmed.)
- Driftchef(Rtg.sjuksköterska)
- Fysiker 20%
- +Läkarkonsulter (Endokrinolog,Kardiolog)

21 oktober 2010 

single	single
photon	photon
emission	transmission
computed	computed
tomografi	tomografi
SPECT	SPTCT

?

21 oktober 2010 

# SPECT-CT

21 oktober 2010 

- SPECT-single photon emission tomography
- PET-positron\* emission tomography
- CT-computed tomography eg. transmissionstomography
- MRT-magnetic resonans tomography

\*En positron är **elektronens antipartikel**. Den har samma massa och har en lika stor men motsatt laddning som elektronen


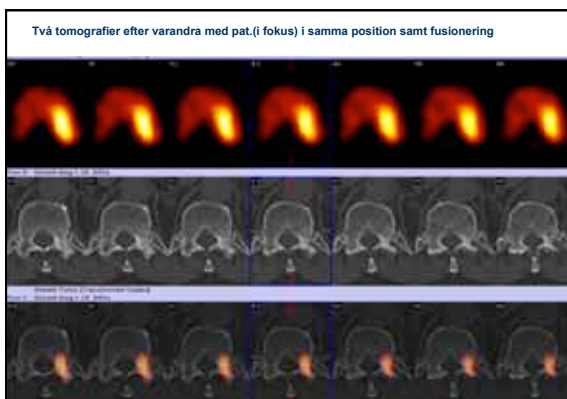
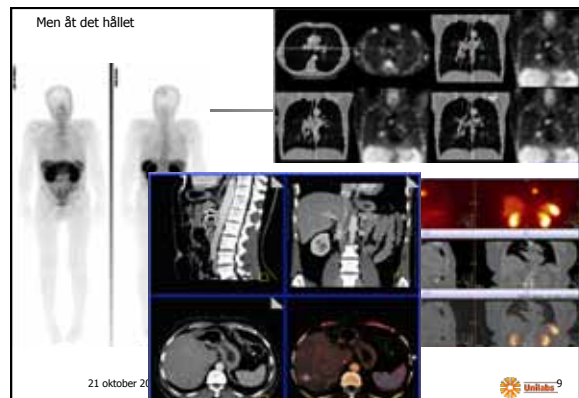
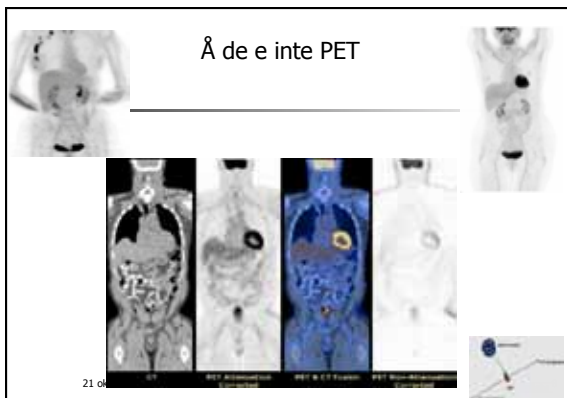
21 oktober 2010



eller


- Isotop-röntgen
- Gamma-CT
- Scint-CT
- Dubbeltomografi
- Dual energi-tomografi
- S-DT
- S-CT

21 oktober 2010

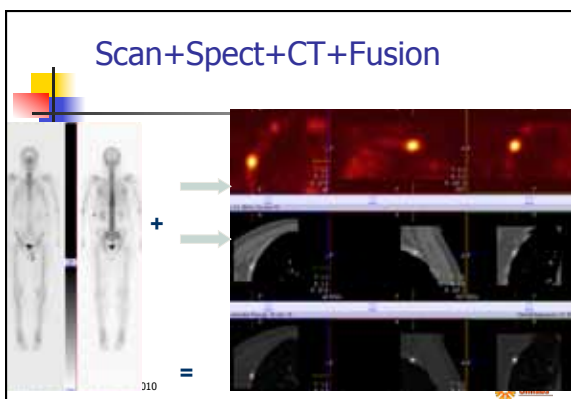

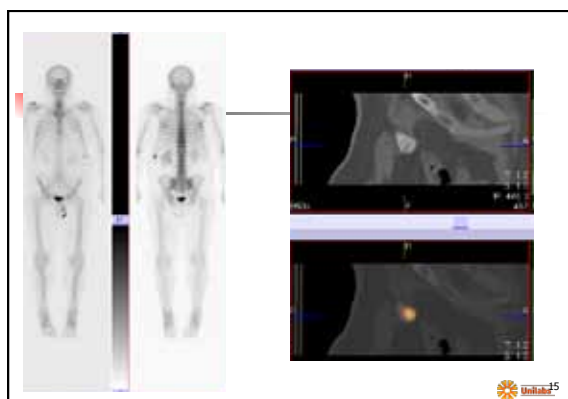



# Skelettscintigrafi

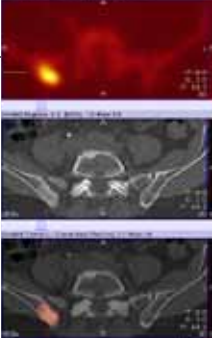
SPECT/CT


# Scan+Spect+CT+Fusion

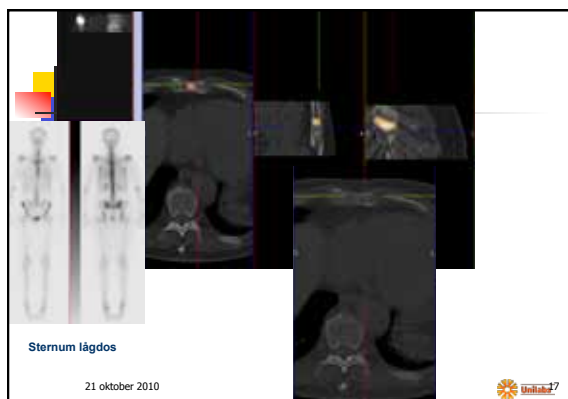
# LÅGDOS-CT




21 oktober 2010



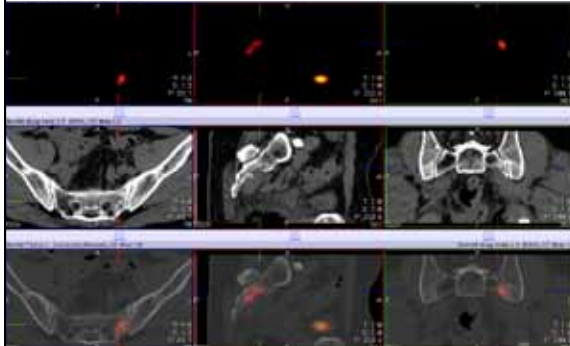
# Sternum lågdos



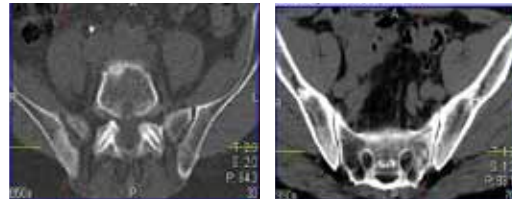
21 oktober 2010



### Hög(diagn.)dos-CT



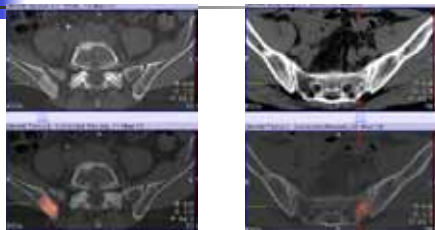
### Låg och hög röntgendor (fusion kontra diagnos)



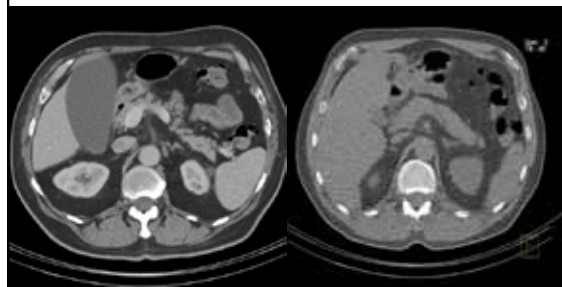
21 oktober 2010



### Kombinationen underlättar



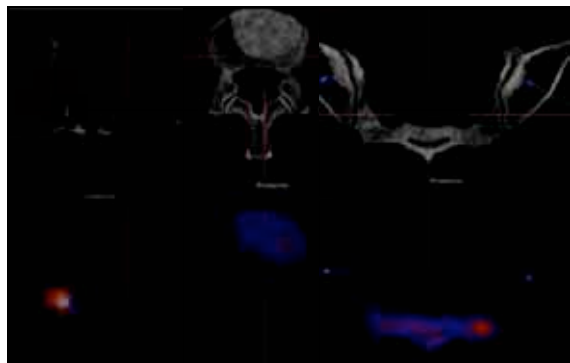
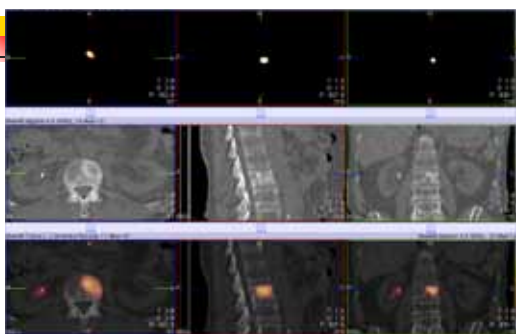
21 oktober 2010



21 oktober 2010



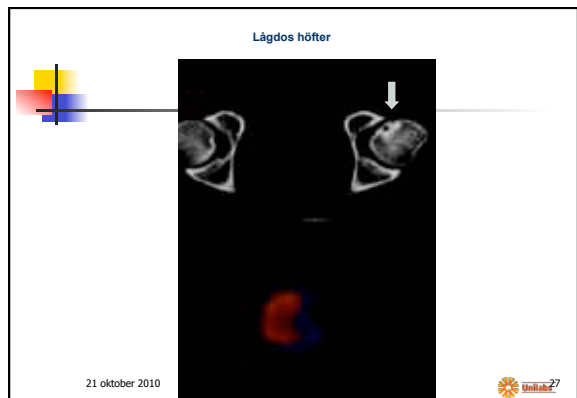
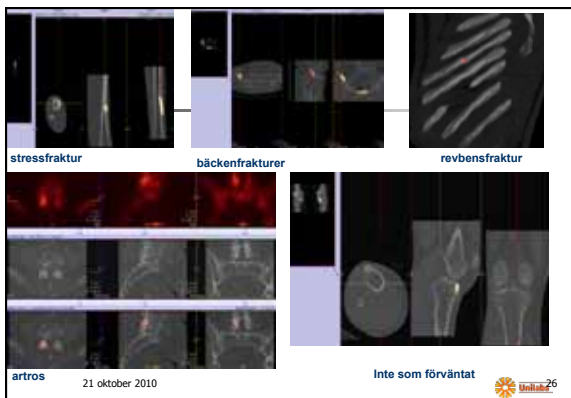
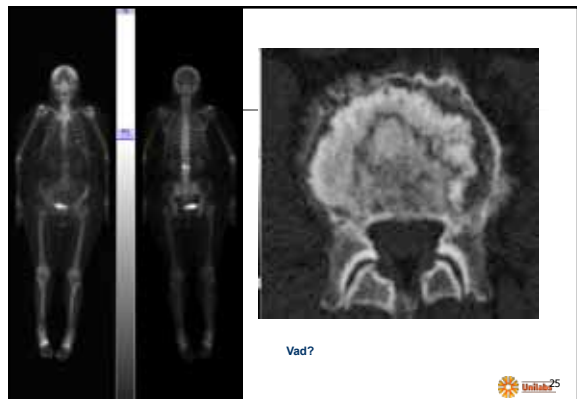
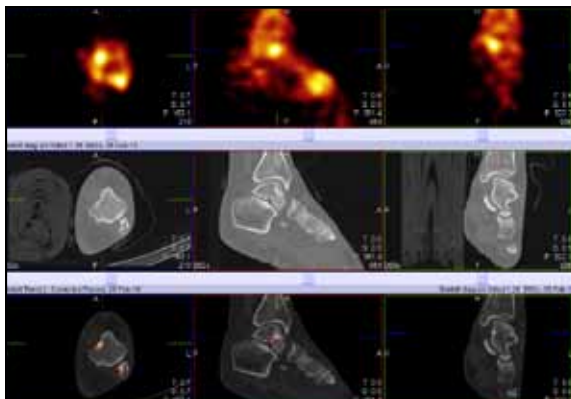
### Lågdos ryg



21 oktober 2010

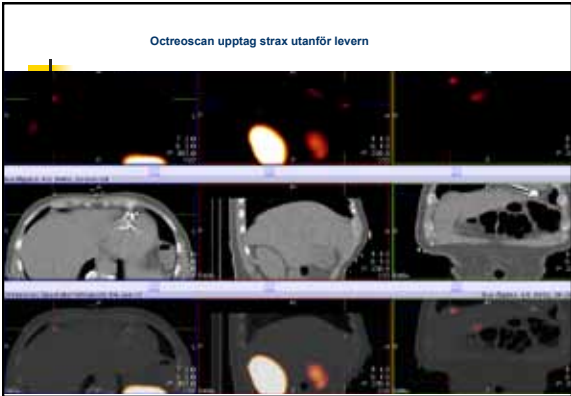
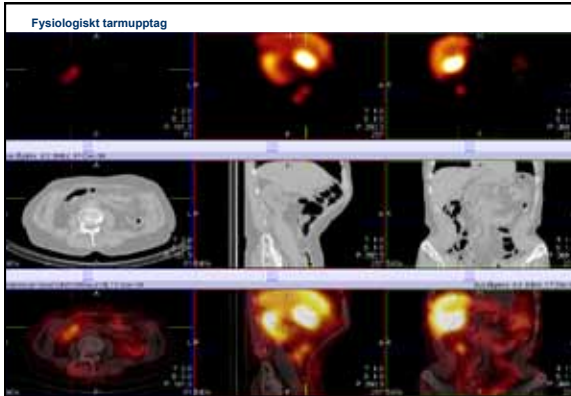
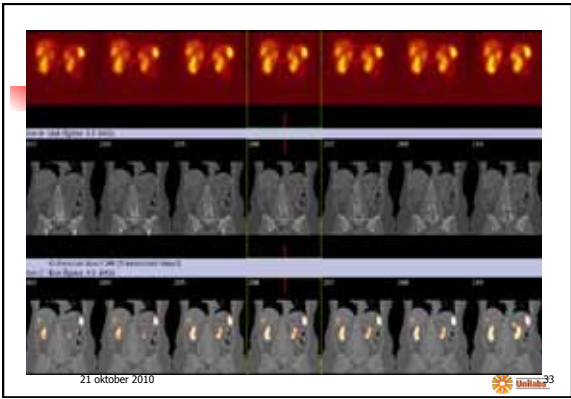
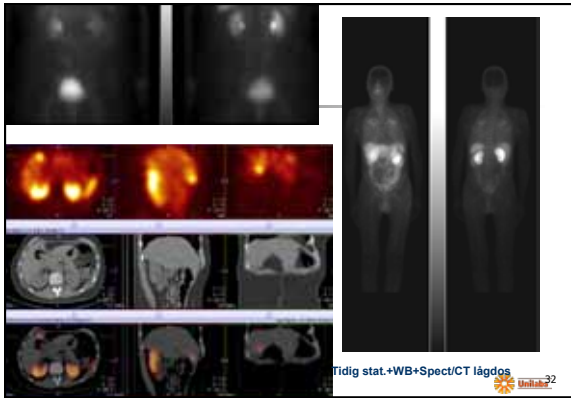
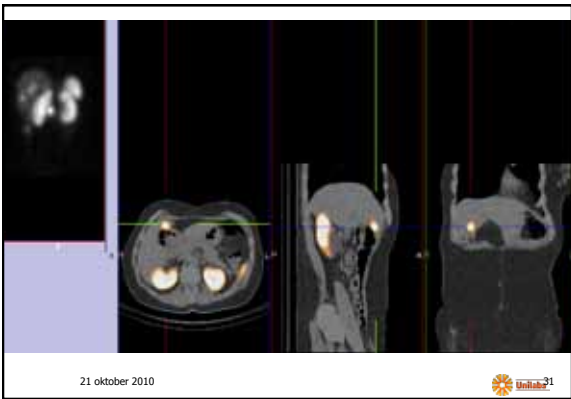
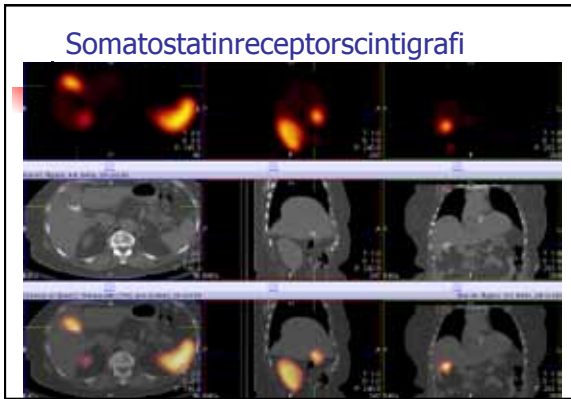
Diagn.CT"allt lyser inte"



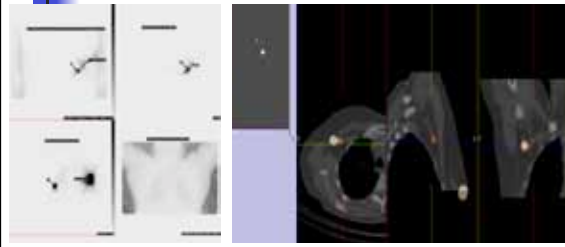


- Låg röntgen dos kontra hög röntgen dos (diagnostisk)
  - Två undersökningar i en seans
  - Tids och dosbesparande
  - Ökar specificiteten för skelettscintigrafi mångfalt
  - I storleksordningen 20-25% av scintigrafierna behöver CT dvs.varje dag
  - Läkarrollen ,behöver bedöma direkt om behov av CT,kolla röntgenarkiv röntgenbilder
  - LågdosCT delegerad till sköterskorna
- 21 oktober 2010

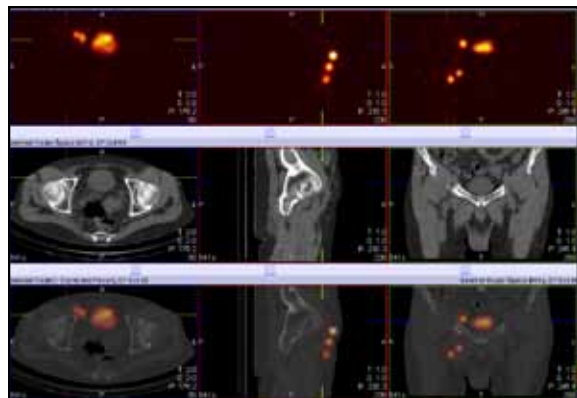
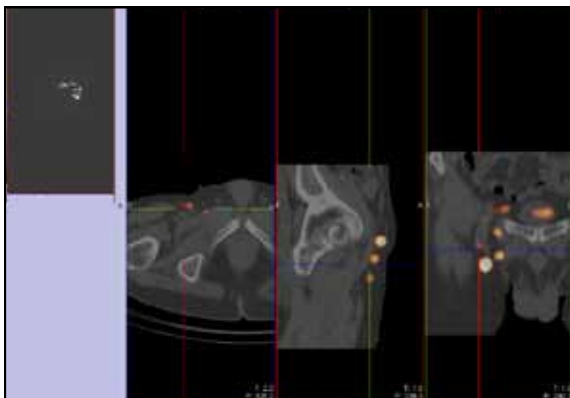
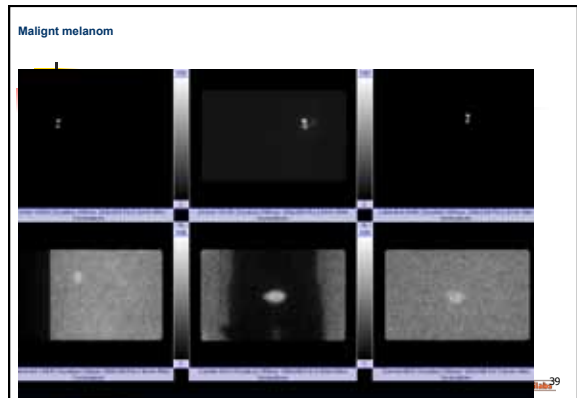
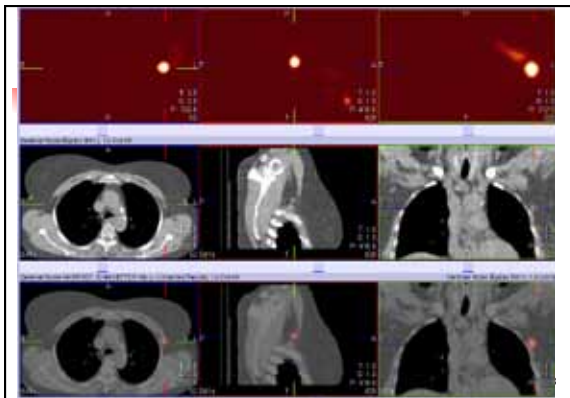
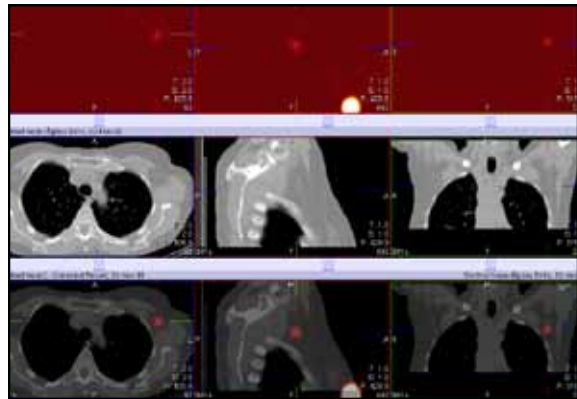
- Lite svårare planera dagen
  - Mycket stimulerande för personal
  - Remitterande läkare och patienter börjar få upp ögonen för logistiken
  - Ex.nydebuterad prostataca. Samtidig skelettscintigrafi och CT buk(diagn.)
  - Octreoscan i samma seans som planerad kontroll med CT buk(diagn.)
- 21 oktober 2010

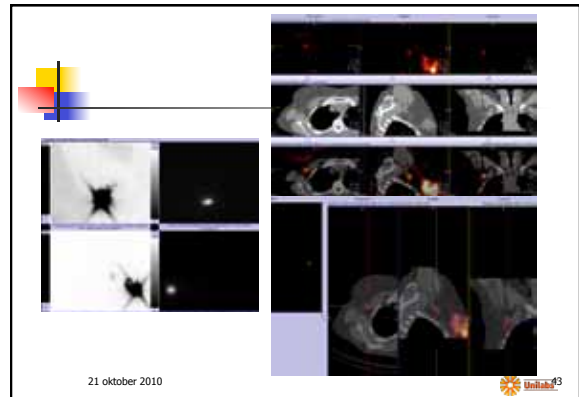
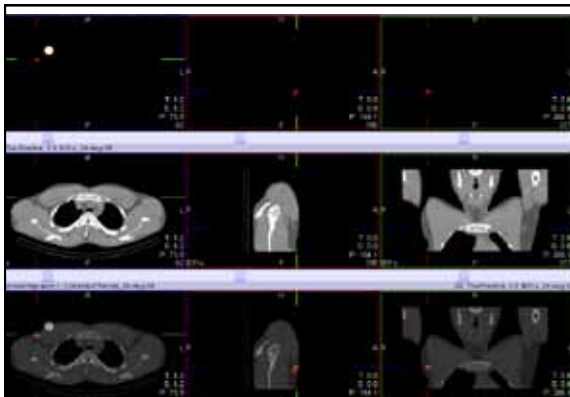


# Sentinel node



21 oktober 2010





21 oktober 2010



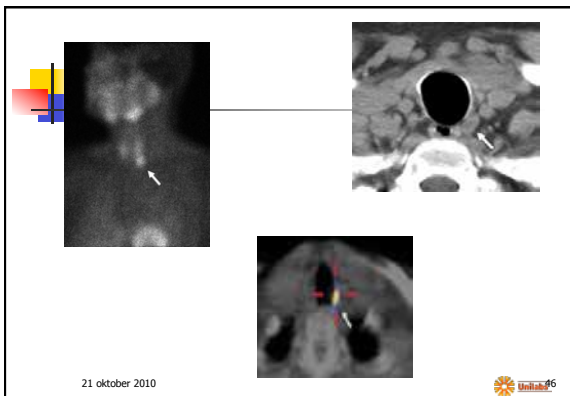
- Spect/CT på alla melanom
- Spect/CT efter överenskommelse med kirurg ,mammarca.

21 oktober 2010

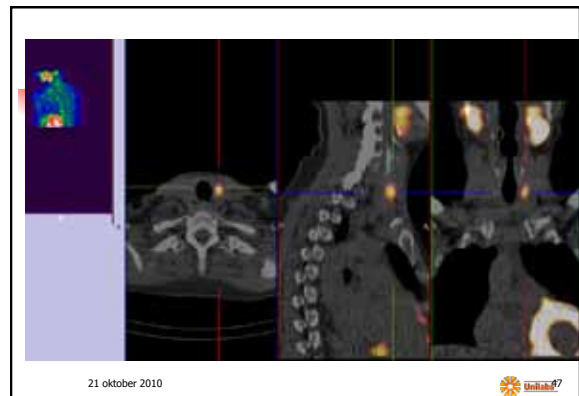


## Parathyroidea

### SPECT/CT



21 oktober 2010



21 oktober 2010



