

## Breast tomosynthesis – Experiences from Malmö

A Tingberg, I Andersson, D Förnvik,  
S Mattsson, T Svahn, P Timberg,  
S Zackrisson

Anders Tingberg

Dept of Radiation Physics, Skåne University Hospital,  
Malmö

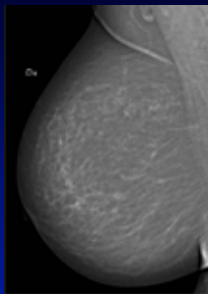
## Mammography is not perfect!

- Relatively low sensitivity (70-80%)
- Particularly difficult in dense breasts
  - 76% of all missed cancers were in dense breasts (Holland et al. Cancer 1982)

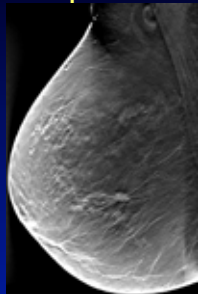
Anders Tingberg

Dept of Radiation Physics, Skåne University Hospital,  
Malmö

## Clinical example



2D mammography



3D imaging – Tomosynthesis

Anders Tingberg

Dept of Radiation Physics, Skåne University Hospital,  
Malmö

## Why so low sensitivity?


- Overlapping tissue
  - All tissue superimposed → no depth resolution
  - Normal tissue may hide lesion
- Lack of radiological contrast
- Tumor growth pattern
  - No tumor nucleus
  - No edge characteristics

Anders Tingberg

Dept of Radiation Physics, Skåne University Hospital,  
Malmö

## Signal-noise ratio – Rose model

- SNR > 5 – object is visible!

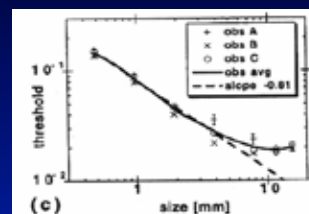


M. Båth, Sahlgrenska Universitetssjukhuset

Anders Tingberg

Dept of Radiation Physics, Skåne University Hospital,  
Malmö

## Rose model and anatomical background (mammography)



Burgess et al., Med. Phys. 2001;28:419-437

Anders Tingberg

Dept of Radiation Physics, Skåne University Hospital,  
Malmö

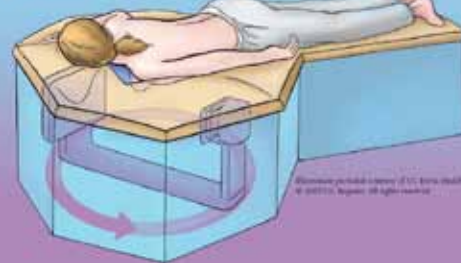## Anatomical background

- The anatomical background is the main reason for non-detection of lesions
- Desirable to reduce the influence of the anatomical background
- Tomographic method reduces influence from overlapping tissue

Anders Tingberg

Dept of Radiation Physics, Skåne University Hospital, Malmö

## Breast CT

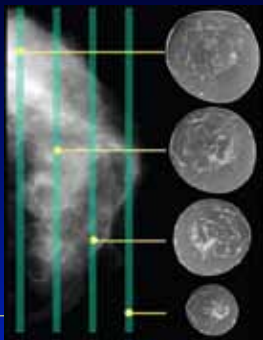


UC Davis

Anders Tingberg

Dept of Radiation Physics, Skåne University Hospital, Malmö

## Breast CT



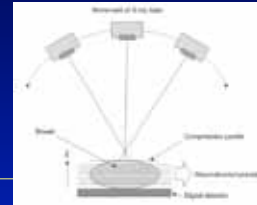
UC Davis

Anders Tingberg

Dept of Radiation Physics, Skåne University Hospital, Malmö


## Breast tomosynthesis (BT)

- 25 projections,  $-25^\circ$  to  $+25^\circ$
- Filtered backprojection  $\rightarrow$  1 mm slice thickness
- Reduces influence of overlapping tissue
- High spatial resolution in image plane
- Similar AGD as 2-view digital mammo (DM)



Anders Tingberg


## Contrast detail phantom, DM



Anders Tingberg

Dept of Radiation Physics, Skåne University Hospital, Malmö

## Contrast detail phantom, BT



Anders Tingberg

Dept of Radiation Physics, Skåne University Hospital, Malmö

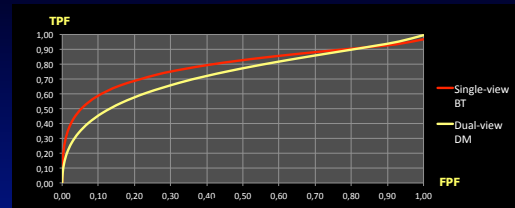


## Breast tomo vs. digital mammo

- 185 cases
  - 89 abnormal (95 lesions)
  - 96 benign/normal
  - Verified with histopathology or 1-year follow-up
- DM (MLO & CC) and BT (MLO)
- Five expert breast radiologists
- Free-response paradigm: Localization and classification of findings

Anders Tingberg Dept of Radiation Physics, Skåne University Hospital, Malmö

## Results and conclusions

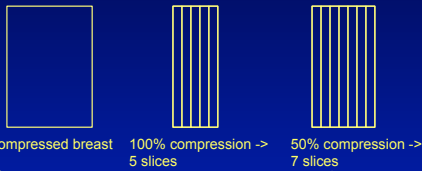


- JAFROC FoM, (1 = perfect result)
  - BT = 0.81
  - DM = 0.71 significant difference ( $p=0.003$ )
- BT had higher diagnostic precision than DM
- Svahn et al. submitted to Radiology 2010

Anders Tingberg Dept of Radiation Physics, Skåne University Hospital, Malmö

## Compression at BT

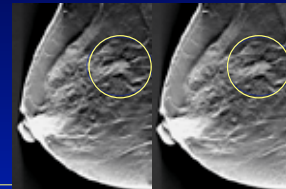
- Is it possible to reduce the compression force at BT compared to DM?
- Possibility for better depth resolution



Anders Tingberg Dept of Radiation Physics, Skåne University Hospital, Malmö

## Compression at BT

- 45 patients imaged with standard and half compression -> No significant difference in image quality
- Förnvik et al. Radiat Prot Dosim, 2010



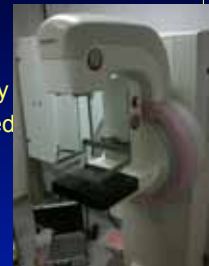Anders Tingberg Dept of Radiation Physics, Skåne University Hospital, Malmö

## Breast cancer screening with tomosynthesis

Anders Tingberg Dept of Radiation Physics, Skåne University Hospital, Malmö

## Screening study

- Compare sensitivity and specificity of BT and DM in a screening population
- Randomized one-armed study
- 15 000 women to be examined with BT and DM
- Estimated time of study: 3 y



Anders Tingberg Dept of Radiation Physics, Skåne University Hospital, Malmö

## Results and experiences

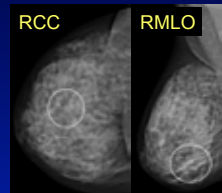
- So far: 600 women examined, 6 verified cancers (normally 3-4 per 1000)
- High amount of paper work (informed consent etc.)
- Adoption of RIS and PACS

Anders Tingberg

Dept of Radiation Physics, Skåne University Hospital, Malmö

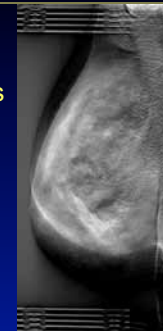
## Reading time

- BT: At least twice as long as DM



Digital mammography

Anders Tingberg

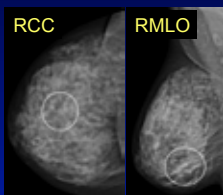


Breast tomo stack (40-80 slices/breast)

Dept of Radiation Physics, Skåne University Hospital, Malmö

## Reading time

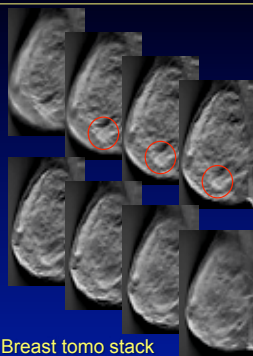
- BT: At least twice as long as DM



Digital mammography

Anders Tingberg

Dept of Radiation Physics, Skåne University Hospital, Malmö



Breast tomo stack (40-80 slices/breast)

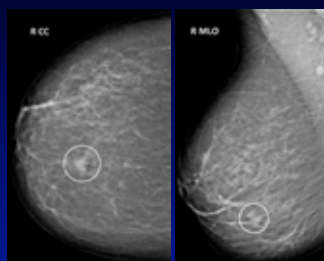
## Data sets

- Large data sets: 0.5 GB per tomosynthesis volume (2816 x 3584 pixels, 85 µm pixel size)
- Problem for current PACS
  - File retrieving
  - Storage

Anders Tingberg

Dept of Radiation Physics, Skåne University Hospital, Malmö

## Another example



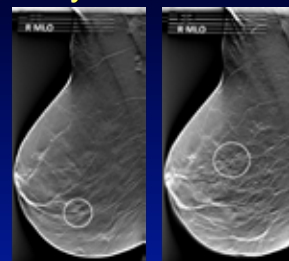
70-y-old woman  
Palpable tumor

- DM: Tumor visible in CC and MLO projections. Confirmed with US

Anders Tingberg

Dept of Radiation Physics, Skåne University Hospital, Malmö

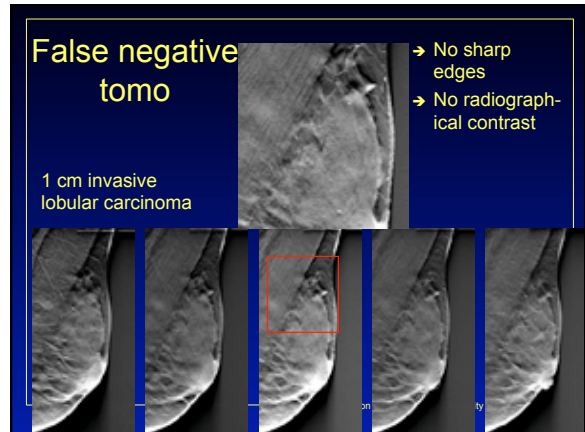
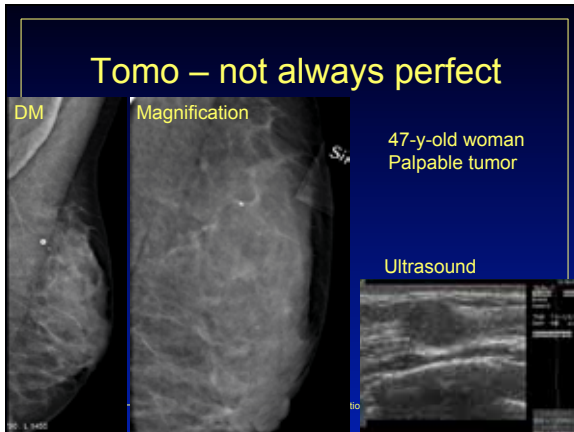
## Tomosynthesis showed...



...multifocal disease

Anders Tingberg

Dept of Radiation Physics, Skåne University Hospital, Malmö



## Conclusions

- Breast tomosynthesis
  - Better diagnostic accuracy than DM
  - Similar dose level as DM
- Potential to replace DM as breast cancer screening modality

Anders Tingberg      Dept of Radiation Physics, Skåne University Hospital, Malmö

## Thank you!

- **Turning Torso of Malmö**
- Santiago Calatrava architect
- 190 m high
- Second highest residential block in Europe
- House is turning 90 degrees

Anders Tingberg      Dept of Radiation Physics, Skåne University Hospital, Malmö